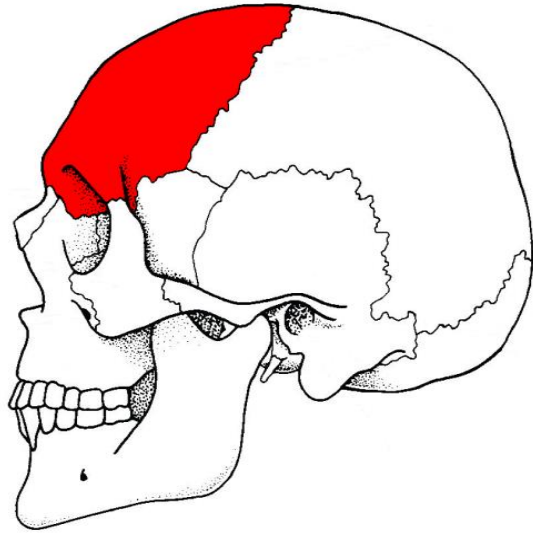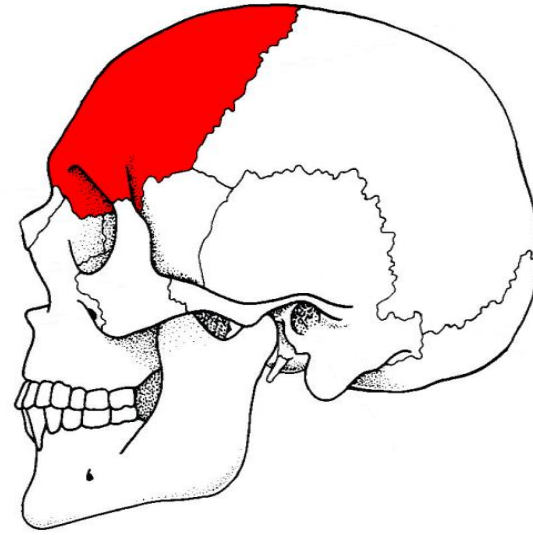
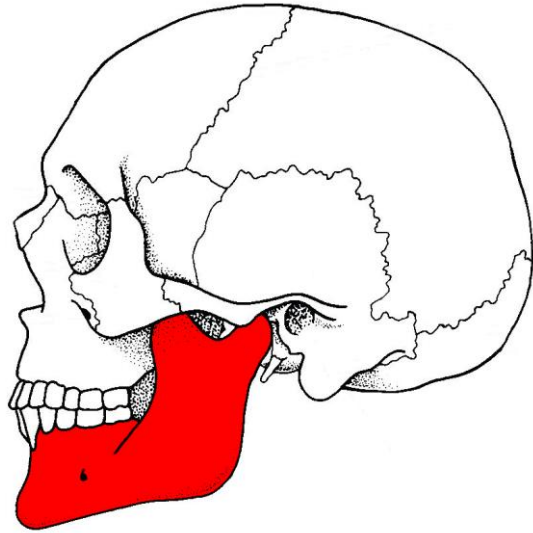


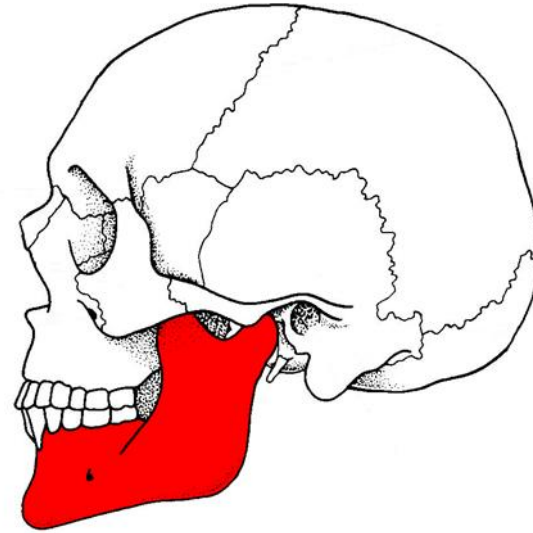
os frontal



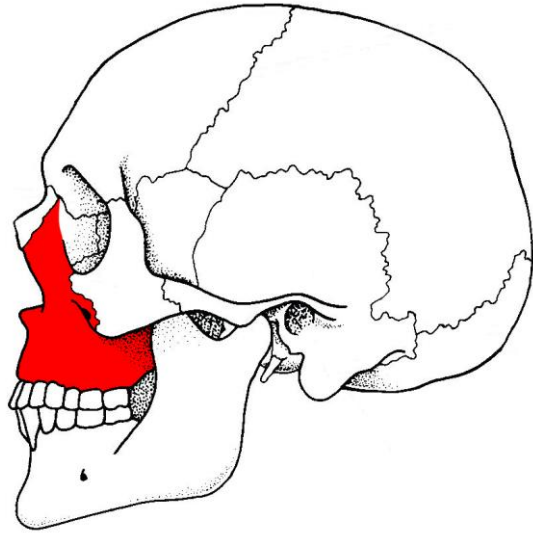
os frontal



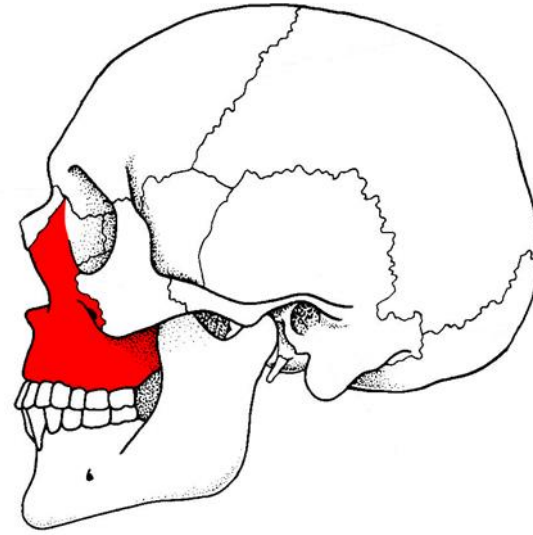
mandibule



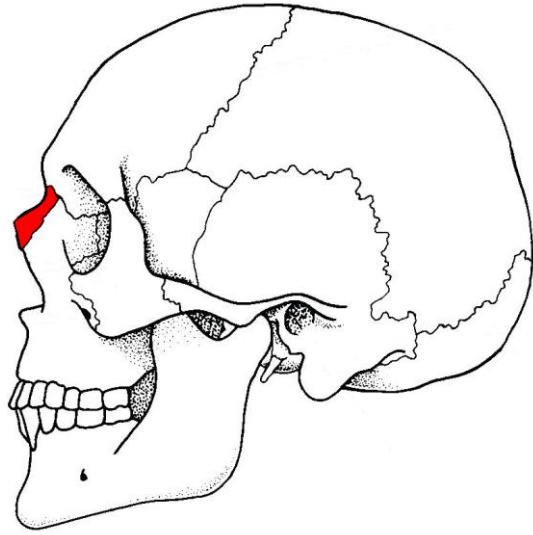
mandibule



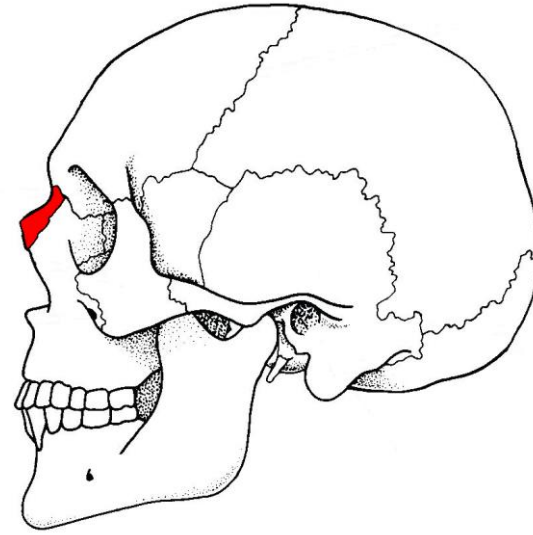
os maxillaire



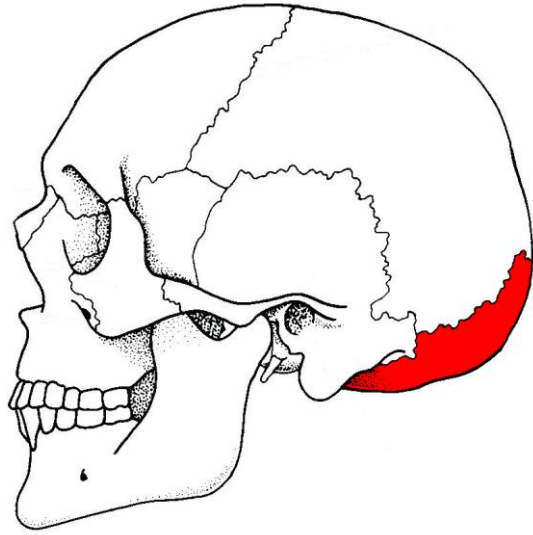
os maxillaire



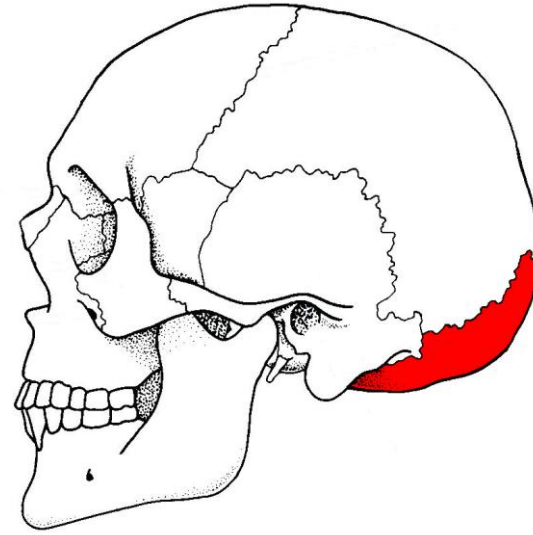
os nasal



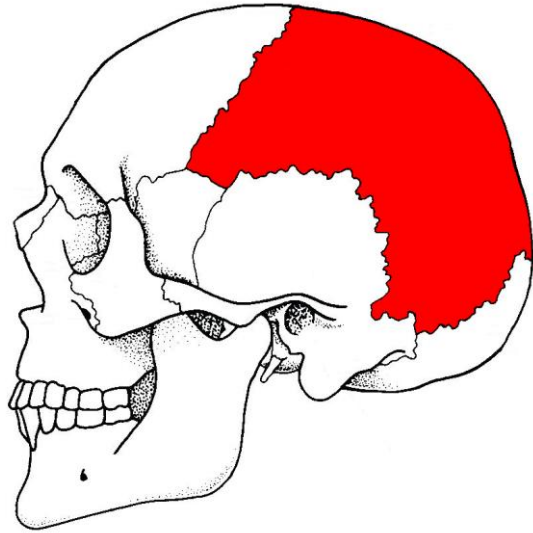
os nasal



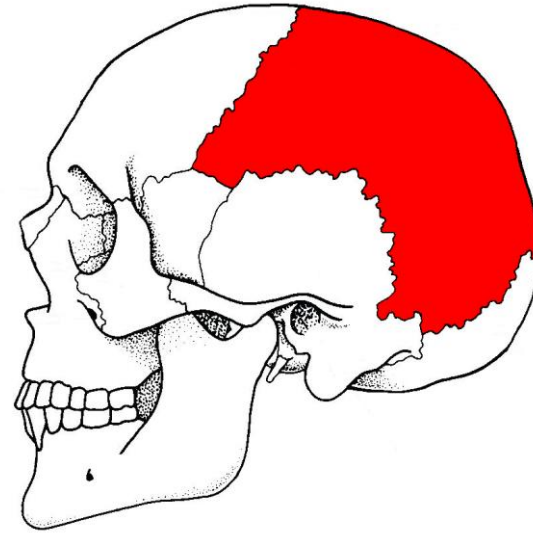
os occipital



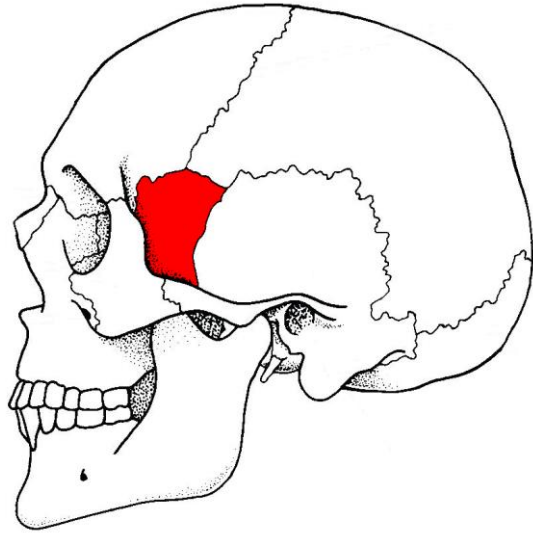
os occipital



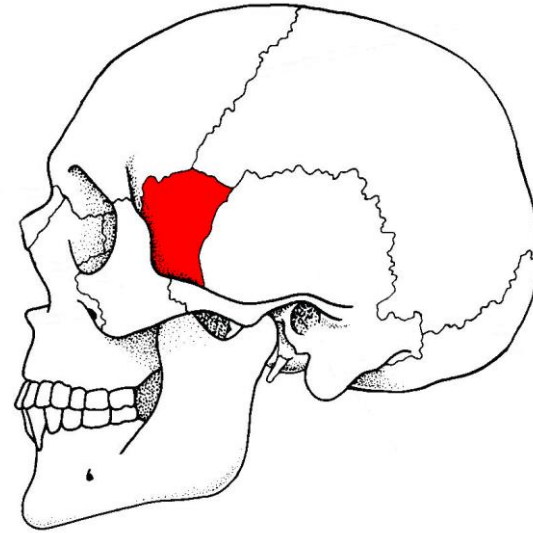
os parietal



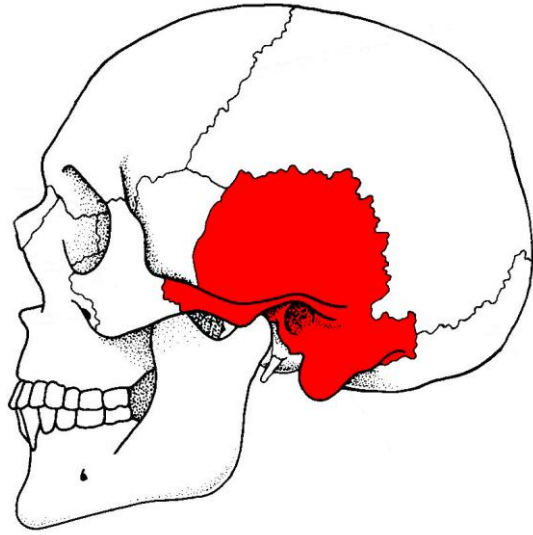
os parietal



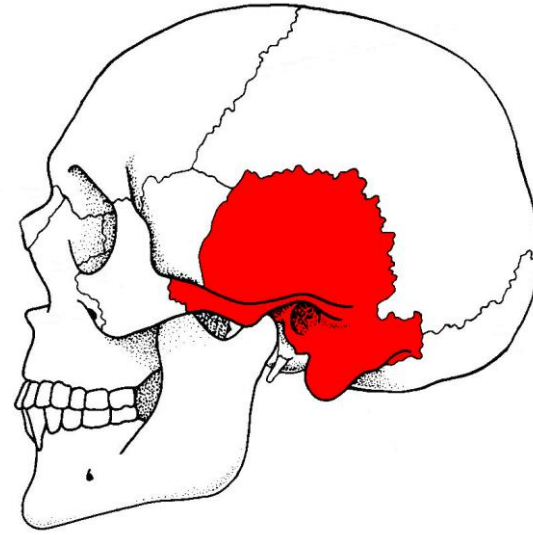
os sphénoïde



os sphénoïde

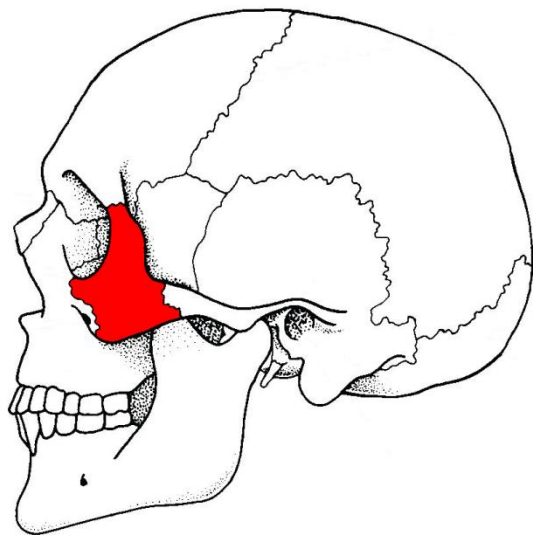


os temporal

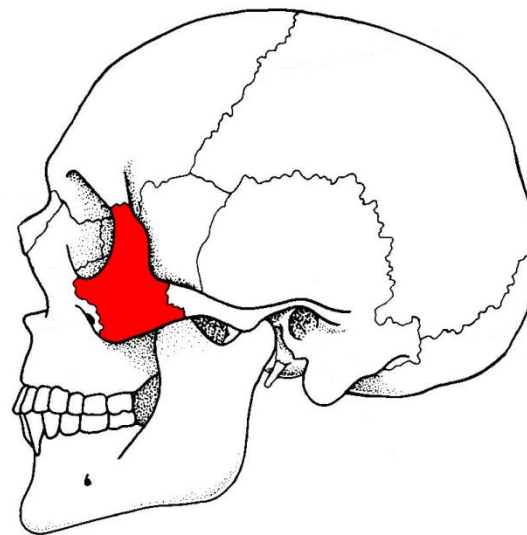


os temporal





os zygomaticque



os zygomaticque