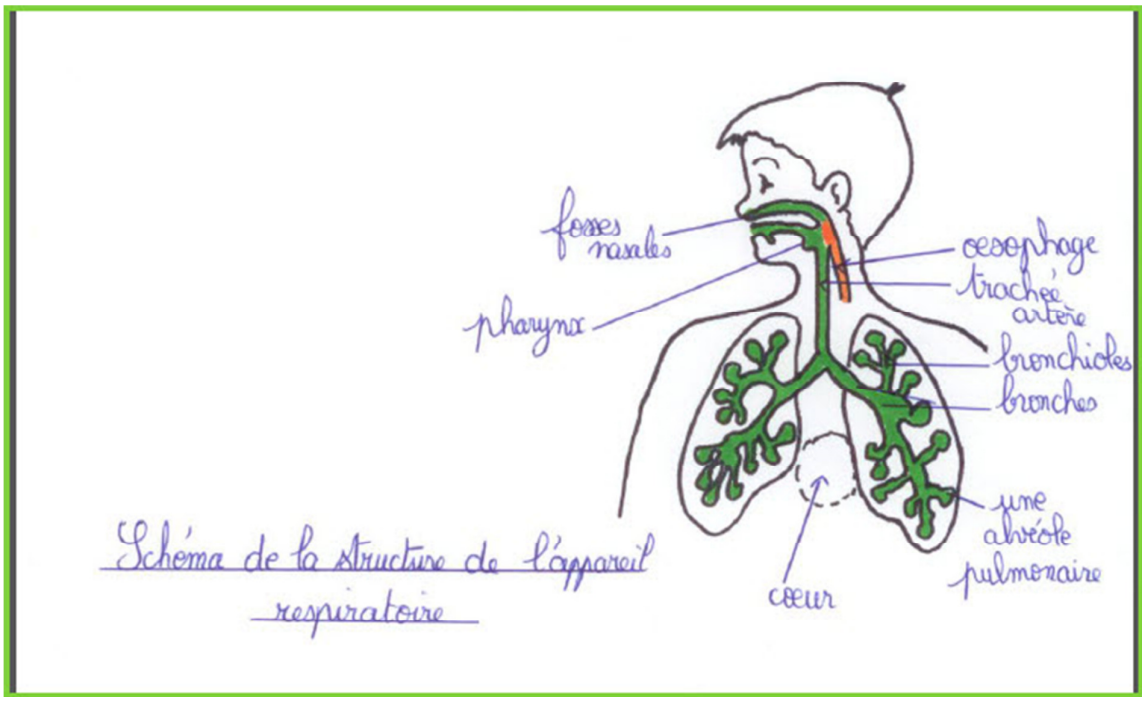
fosses nasales
pharynx
oesophage
trachée artère
bronchioles
bronches
une alvéole pulmonaire
coeur
Schéma de la structure de l'appareil respiratoire

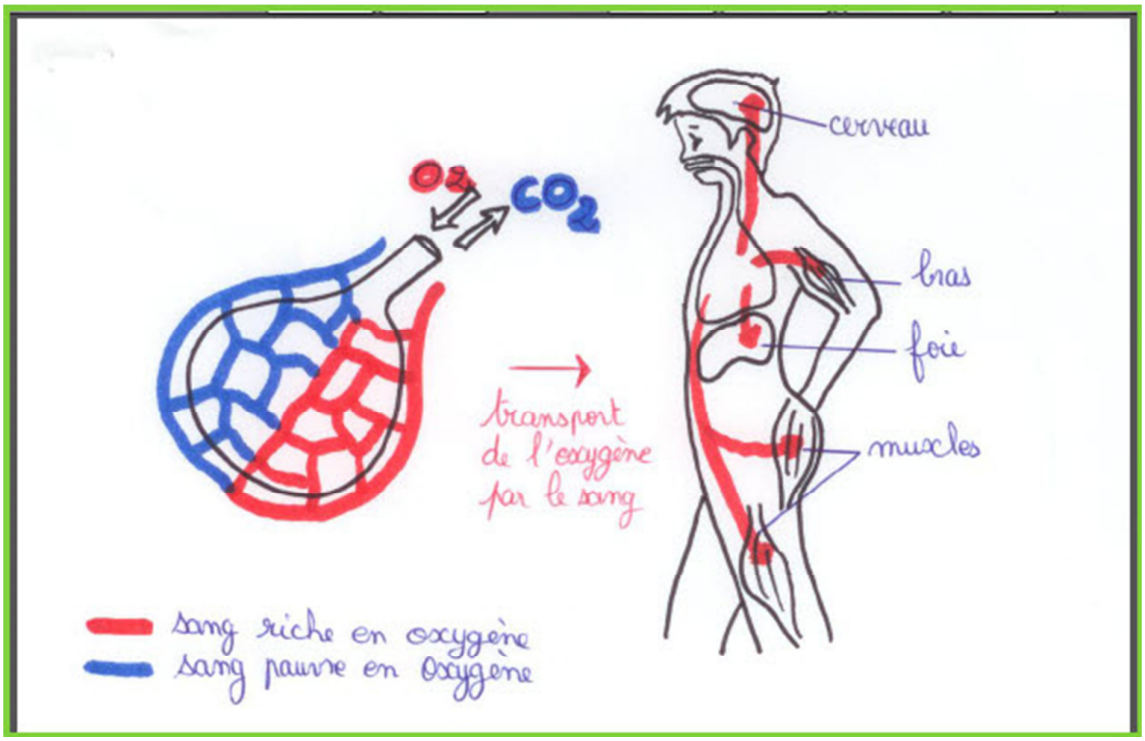
O2
CO2
transport de l'oxygène par le sang
cerveau
bras
foie
muscles
sang riche en oxygène
sang pauvre en oxygène
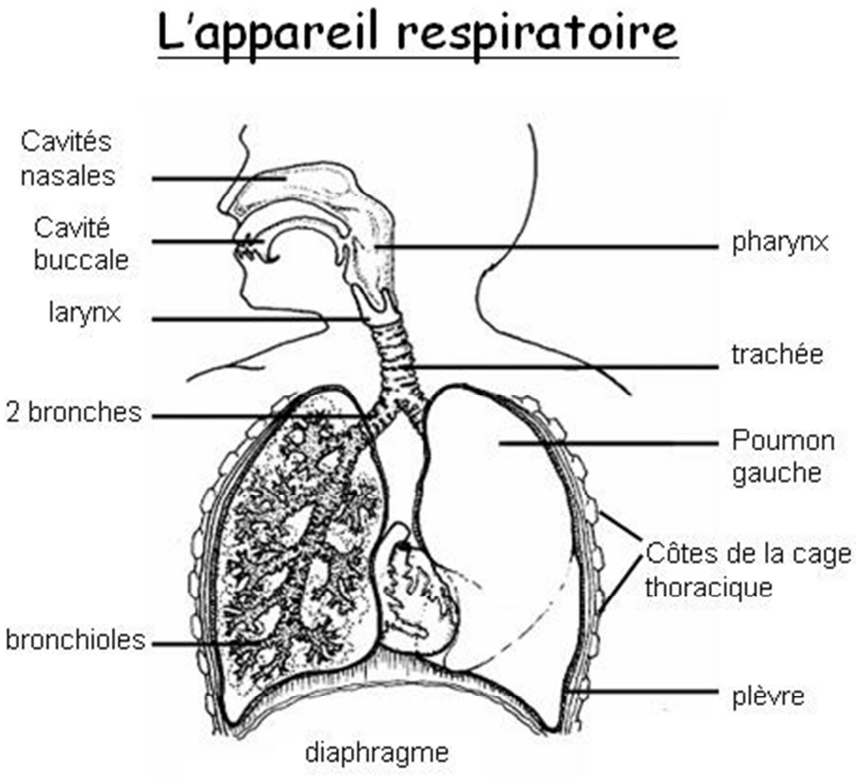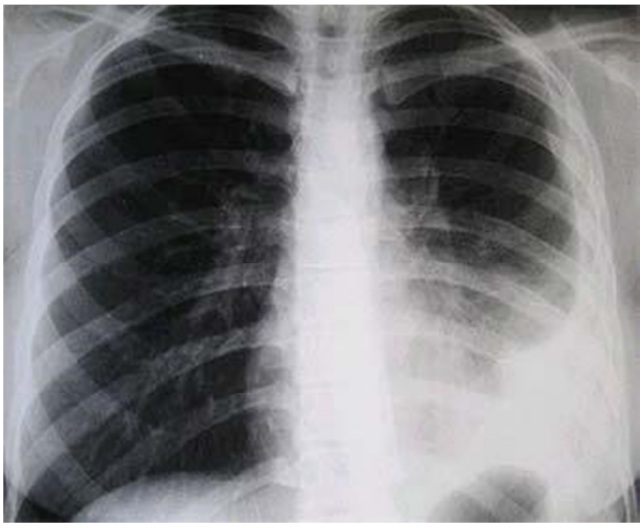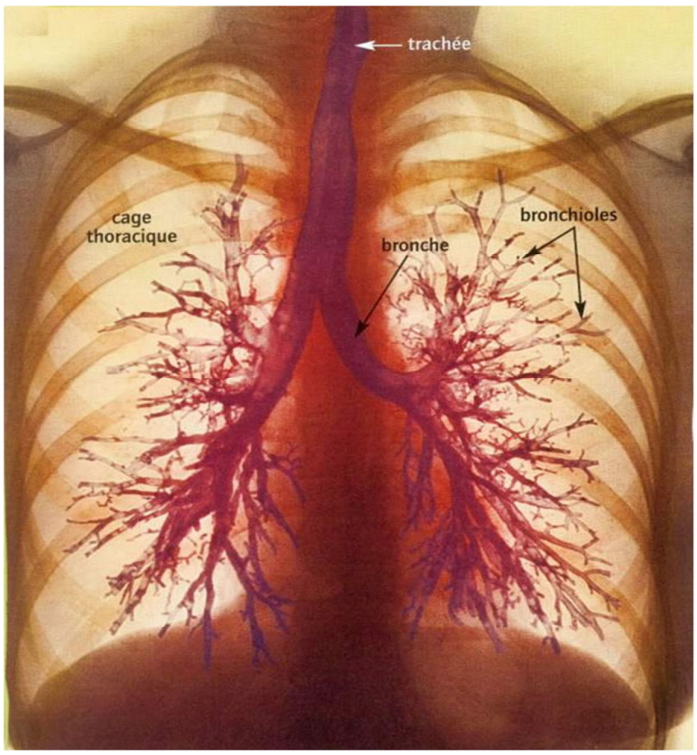
Schéma de l'appareil respiratoire
Source : http://s194590321.onlinehome.fr/cours5P22013.html