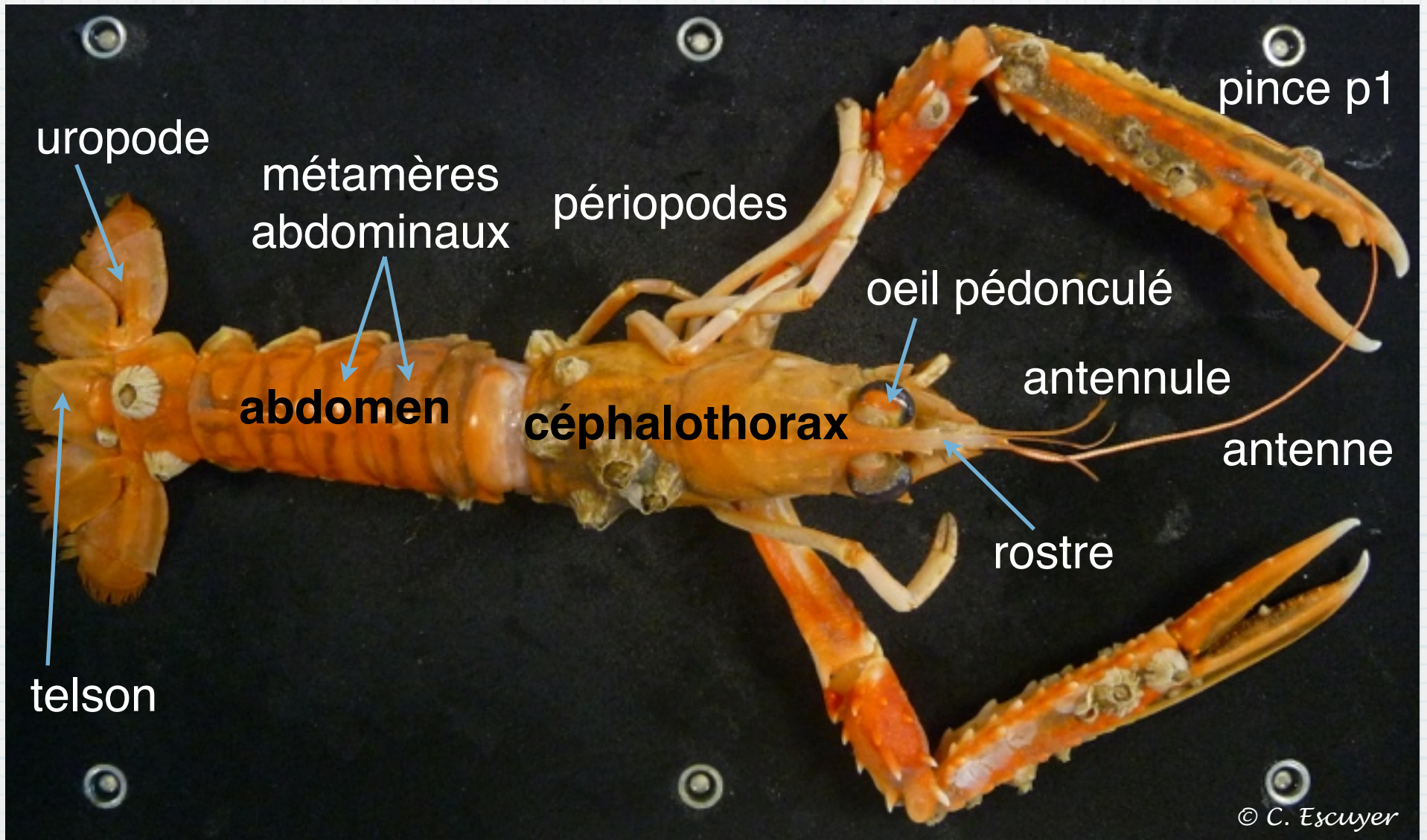


La langoustine

Images de la séance



© C. Escuyer



uropode

métamères
abdominaux

périopodes

pince p1

oeil pédonculé

antennule

abdomen

céphalothorax


antenne

rostre

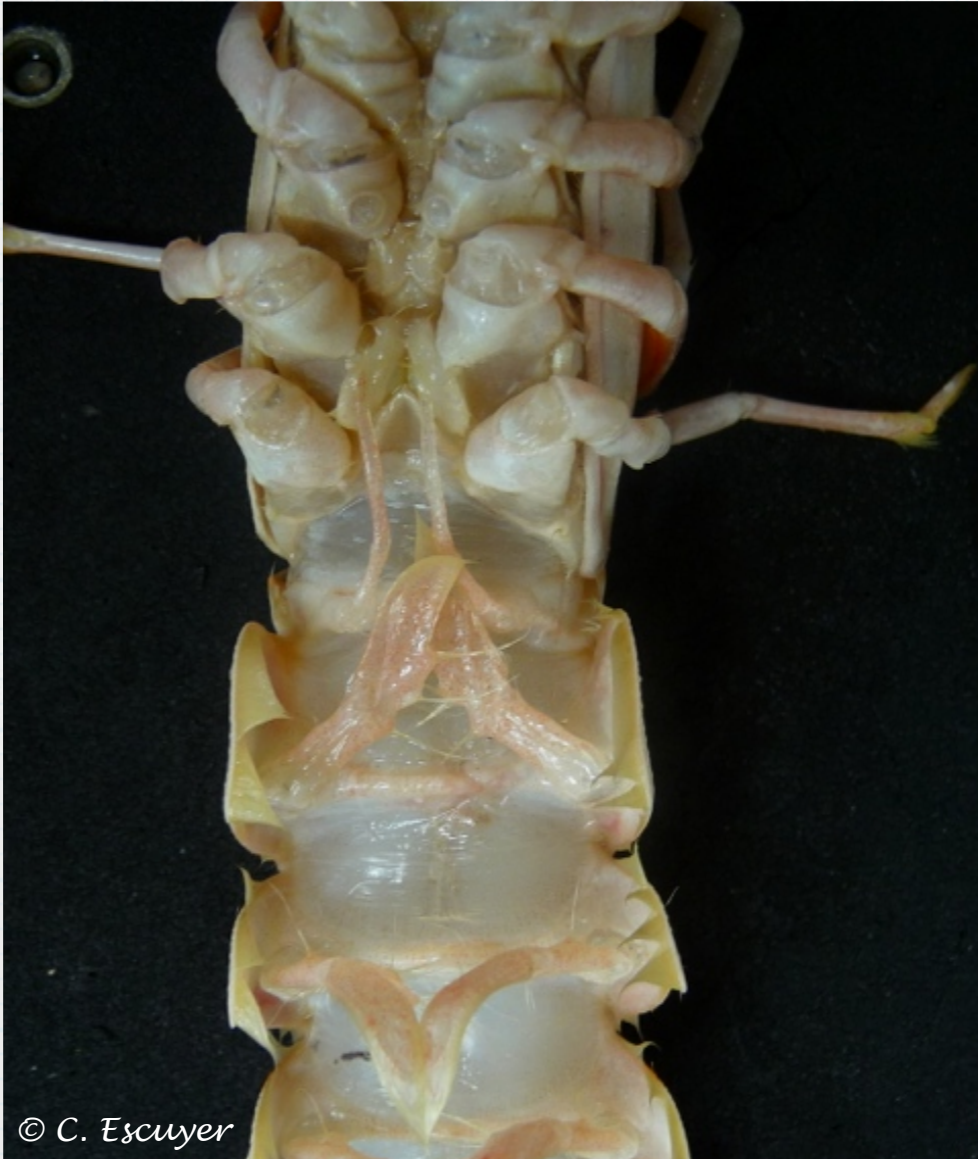telson



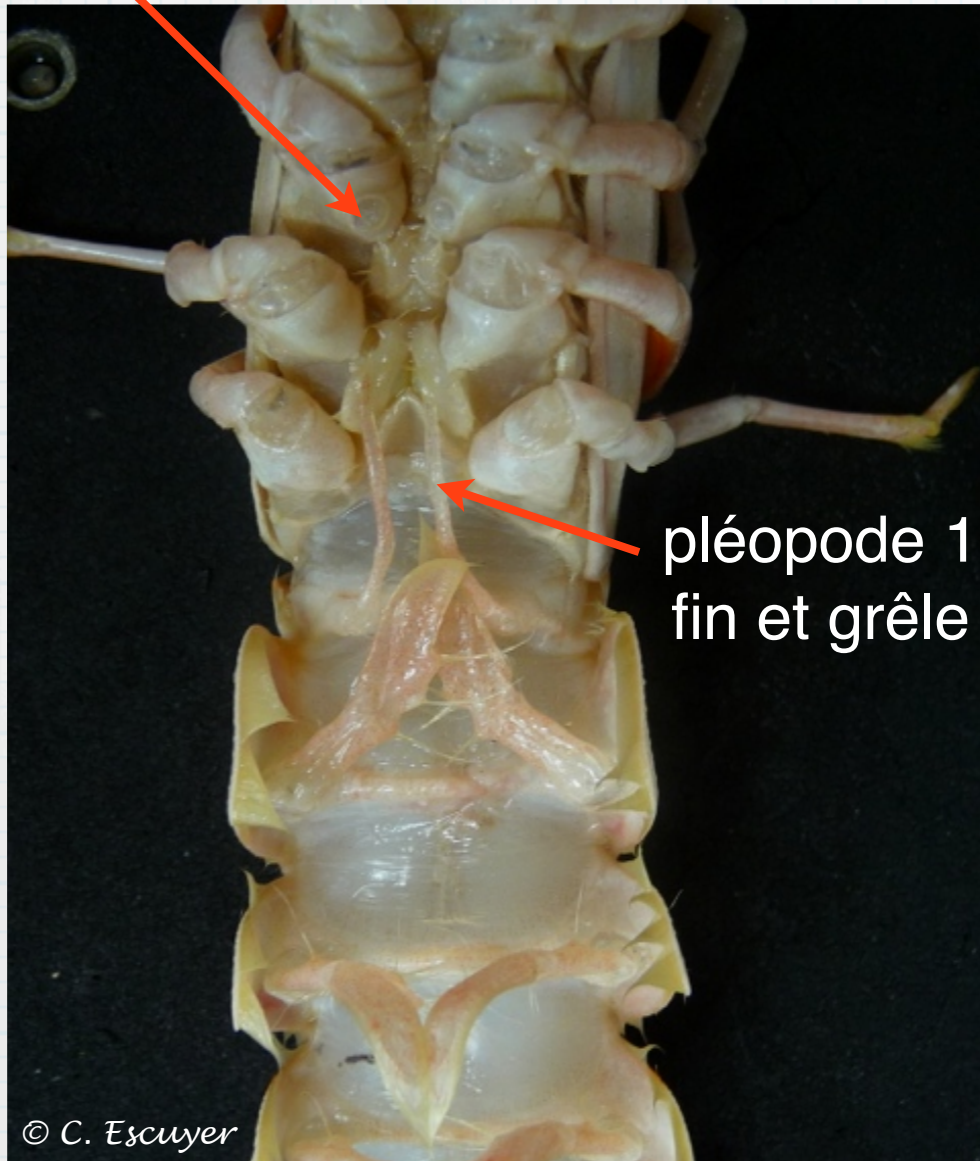
© C. Escuyer



Mâle ou femelle ?

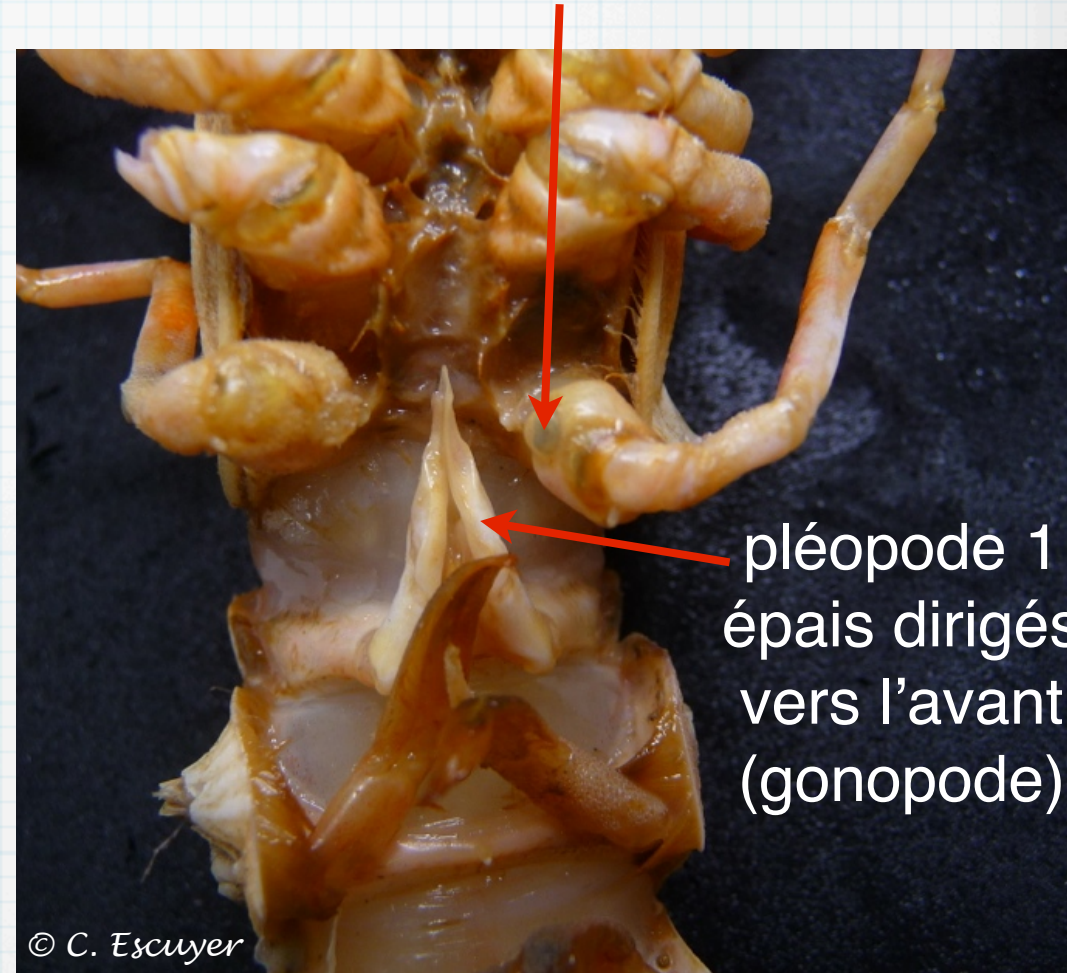


orifice génital
à la base de p3



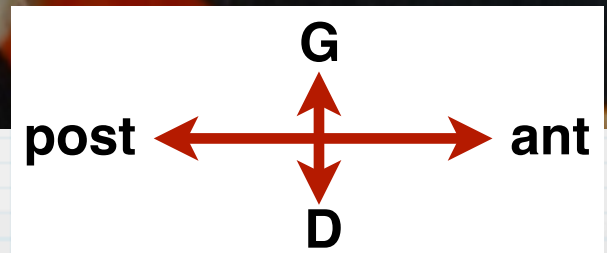
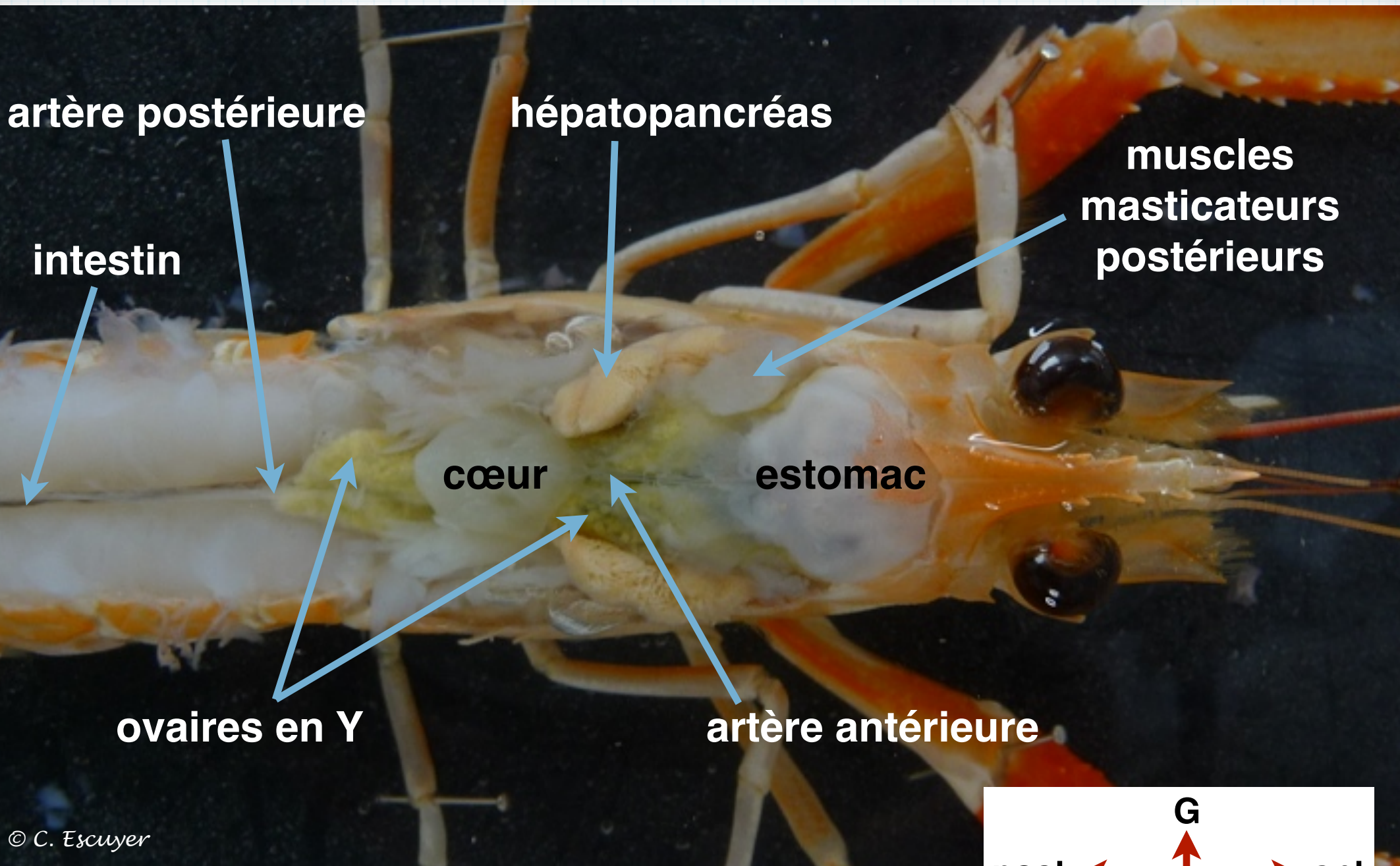
Femelle

orifice génital
à la base de p5

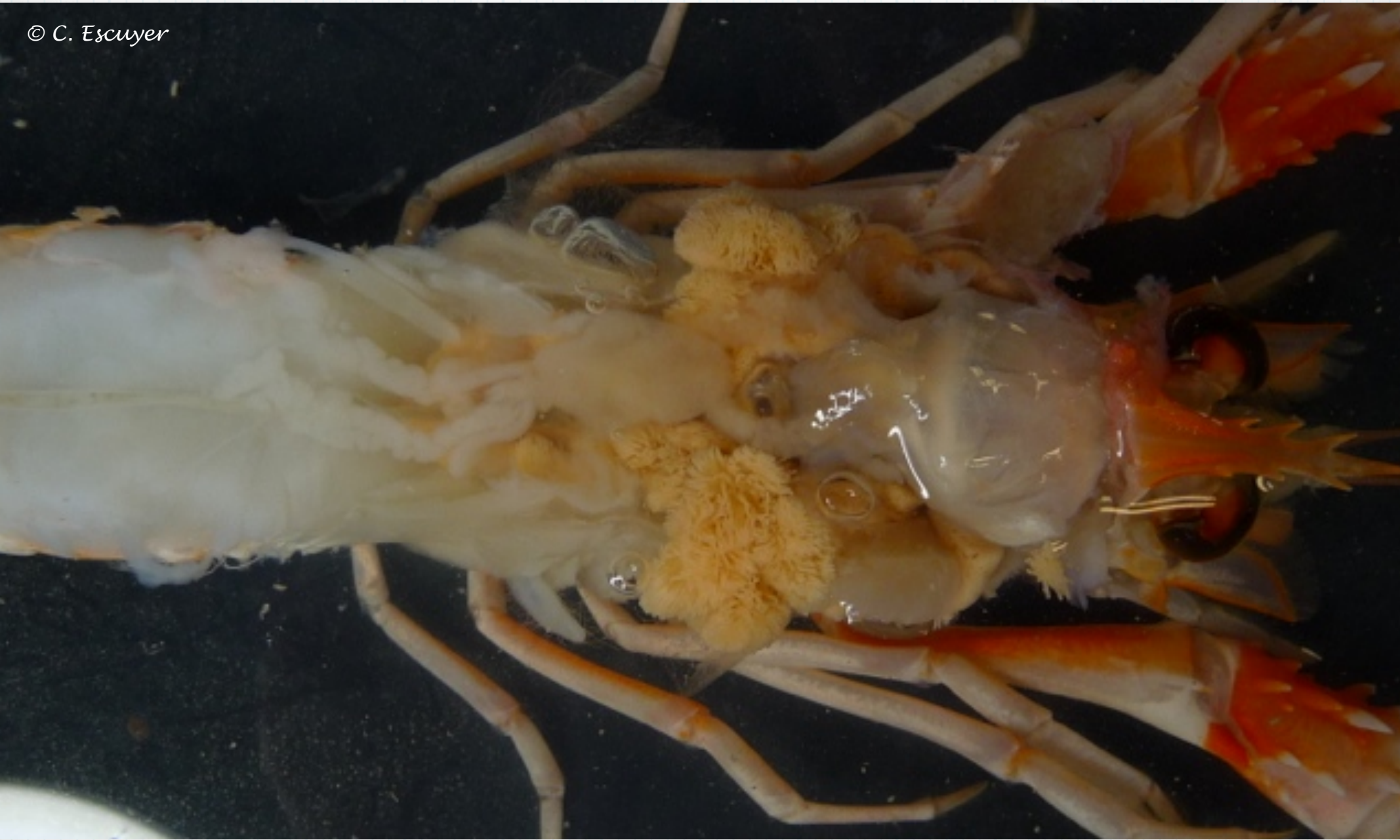

Mâle

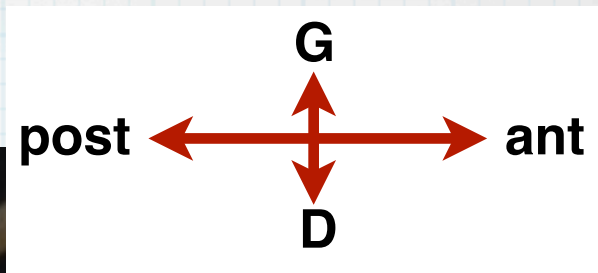




© C. Escuyer



© C. Escuyer



artère postérieure

hépatopancréas

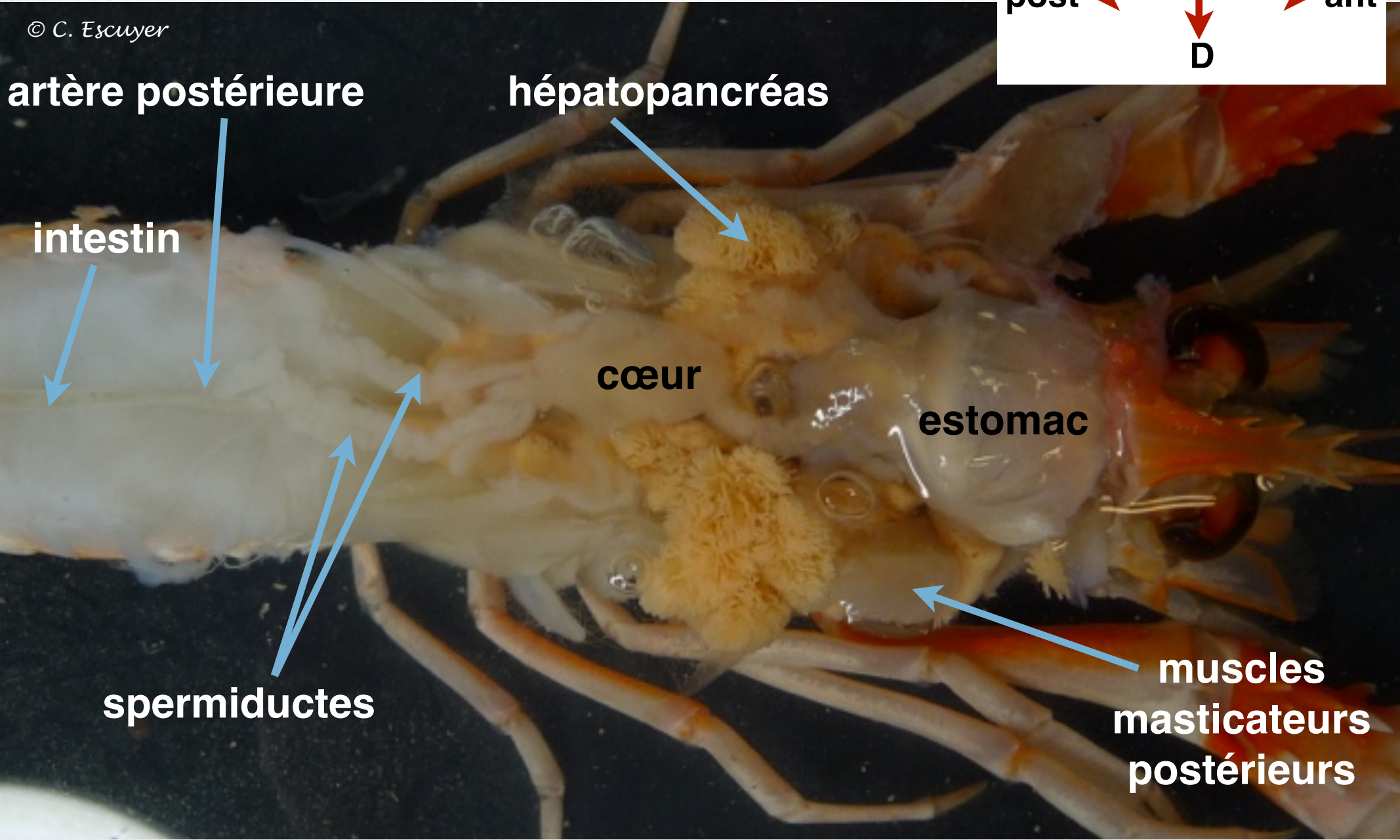
intestin

cœur

estomac

spermiductes

**muscles
masticateurs
postérieurs**



© C. Escuyer



© C. Escuyer

artère postérieure

hépatopancréas

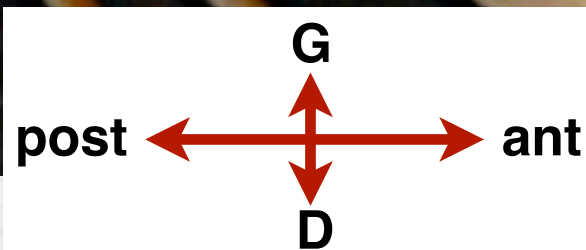
intestin

cœur

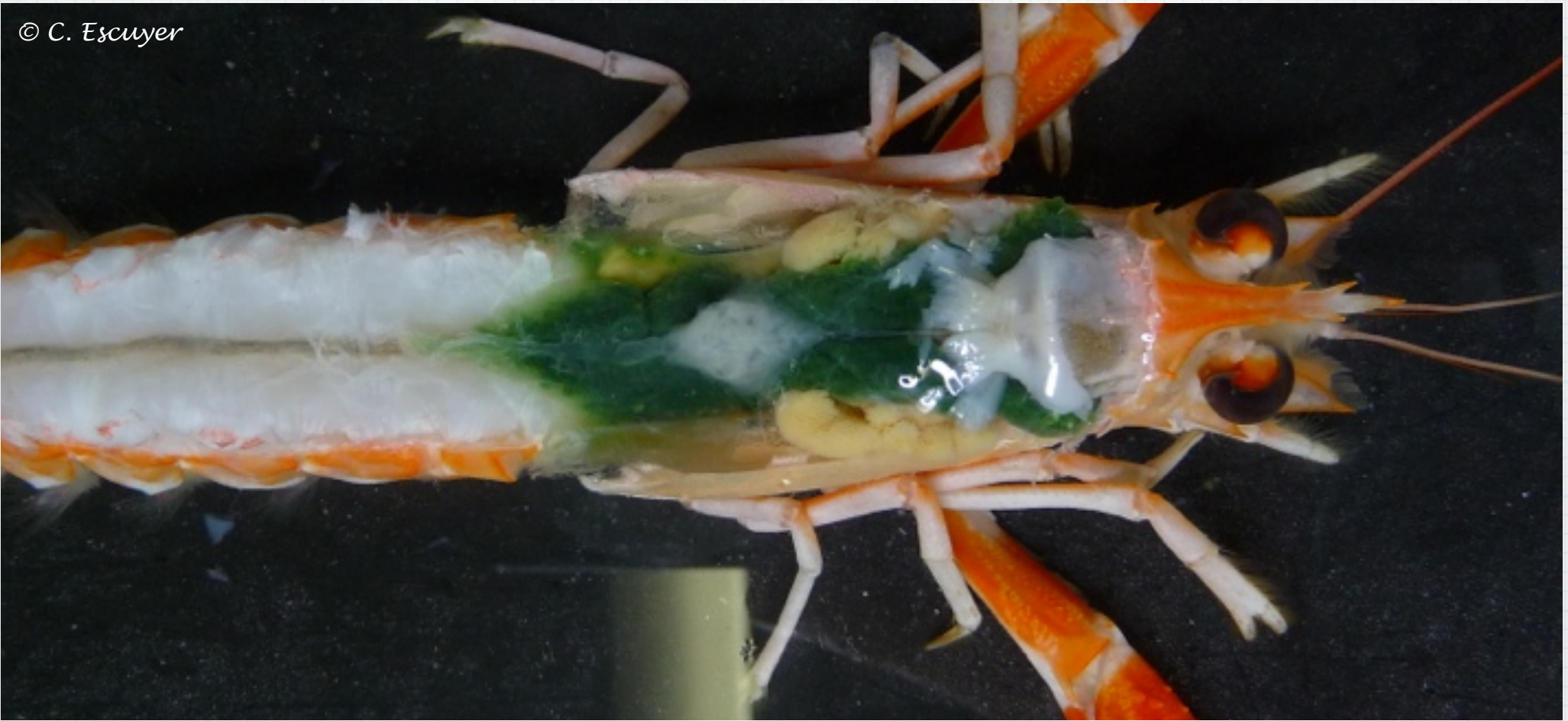
estomac

ovaires en Y

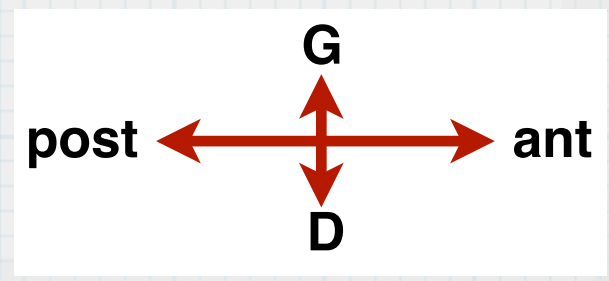
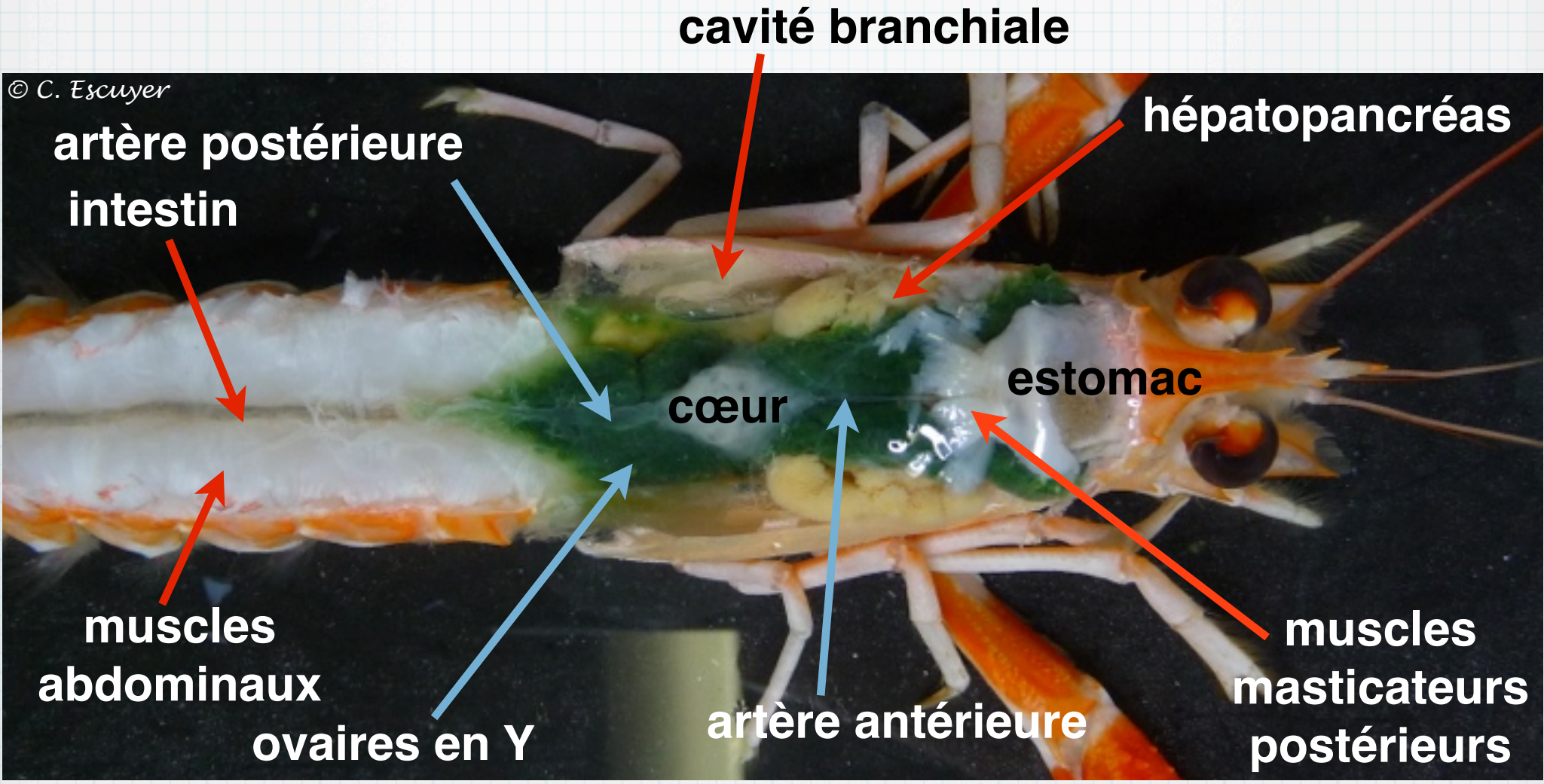
muscles
masticateurs
postérieurs



© C. Escuyer



© C. Escuyer

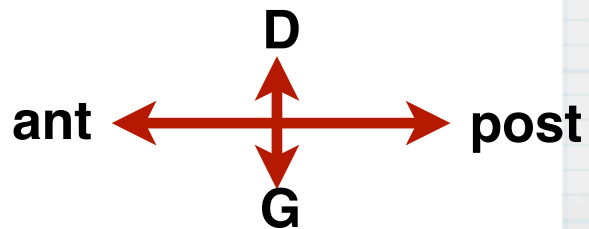
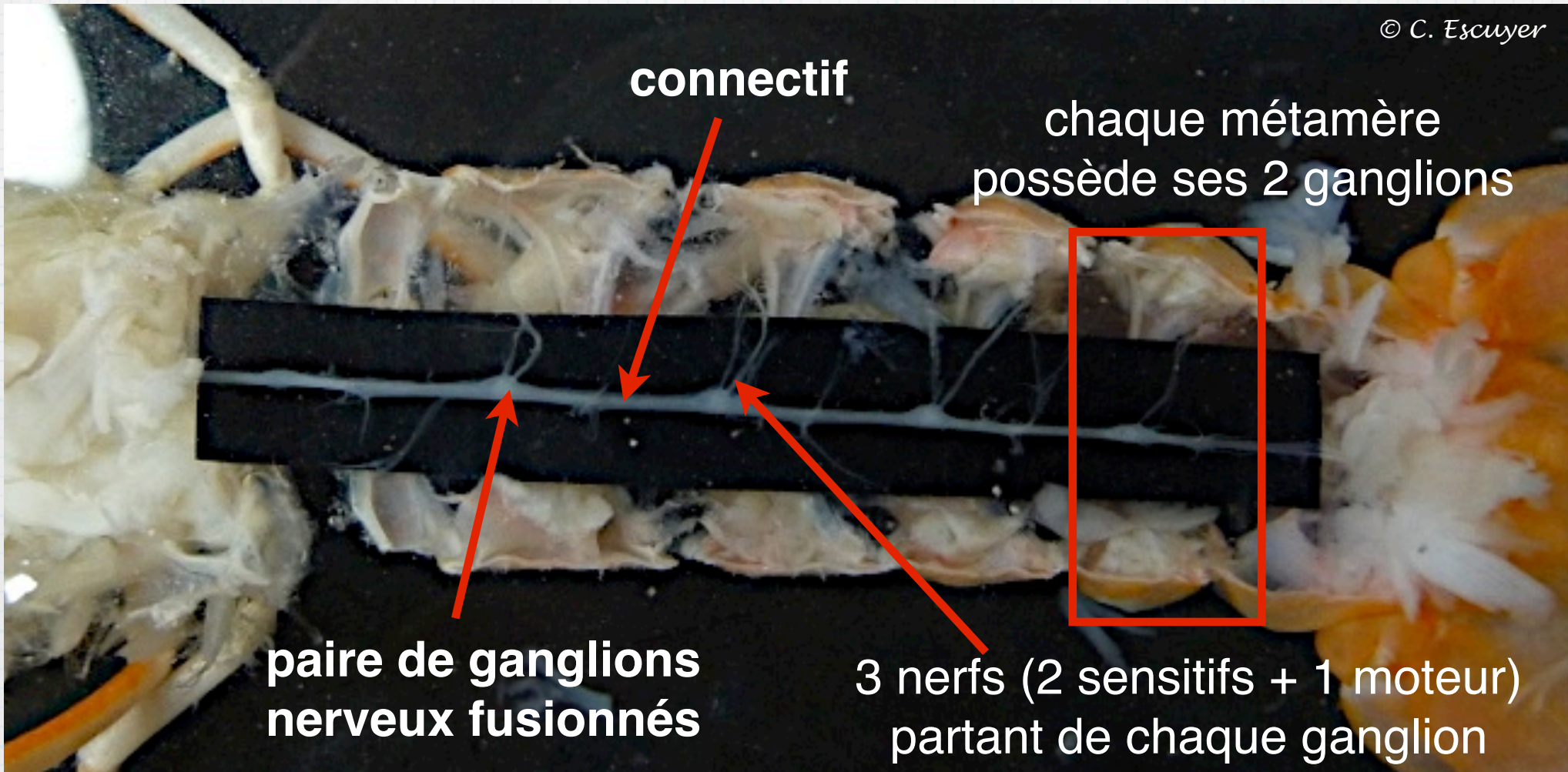


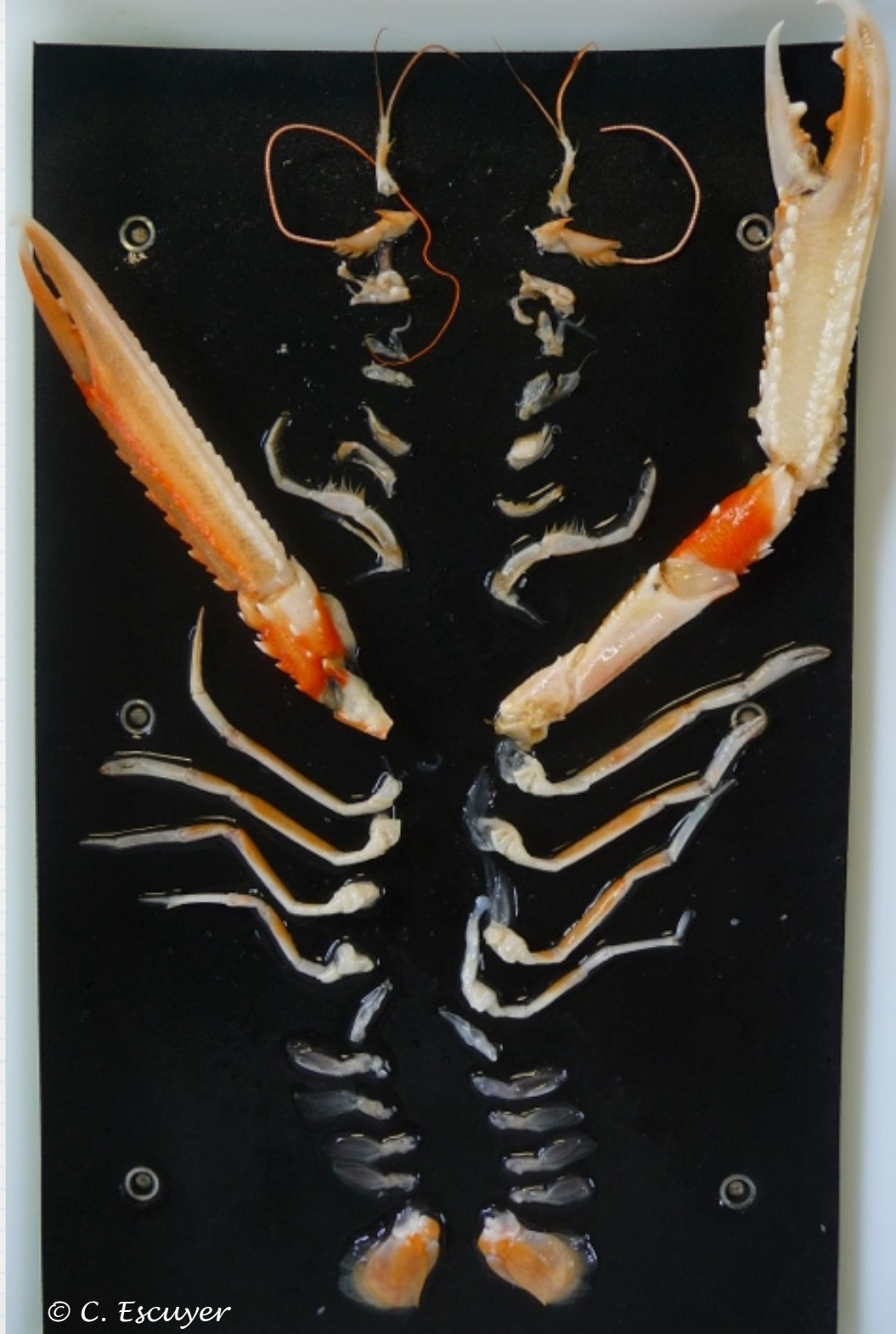© C. Escuyer



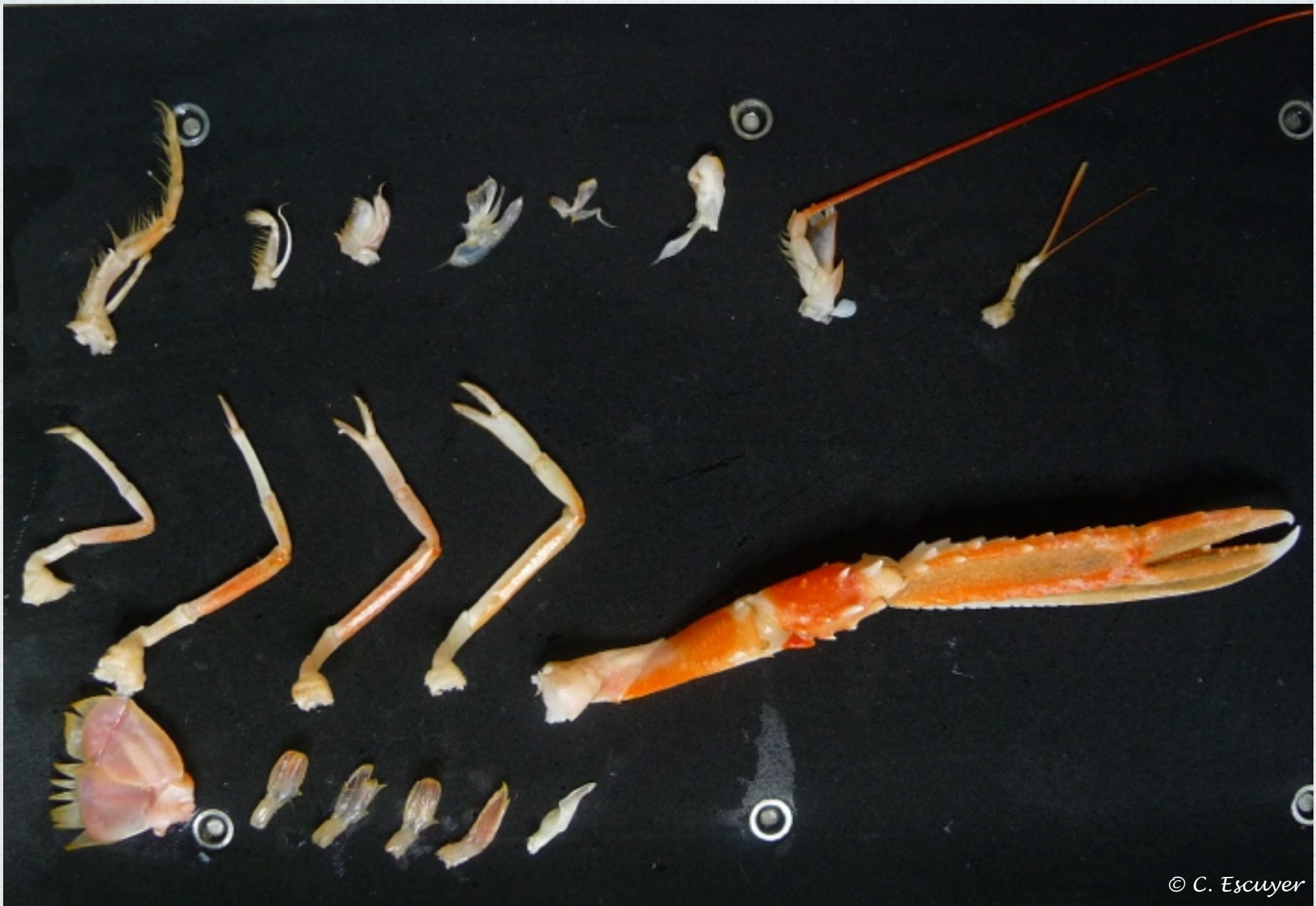La chaîne nerveuse ganglionnaire

© C. Escuyer





© C. Escuyer



pattes mâchoires pmx

pmx 3

pmx 1

maxillule

pmx 2

maxille

mandibule

antenne

antennule

p5

p4

p3

p2

périopode p1 (pince)

Appendice céphalique
Appendice thoracique
Appendice abdominal

uropode

pléopodes 1 à 5

pléopode 1 = gonopode mâle

pléopode 6