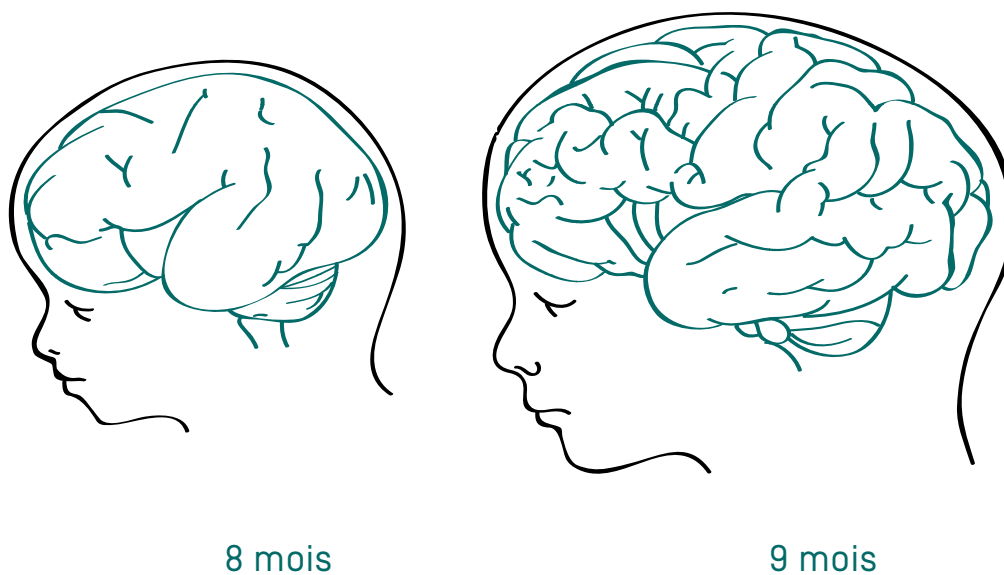
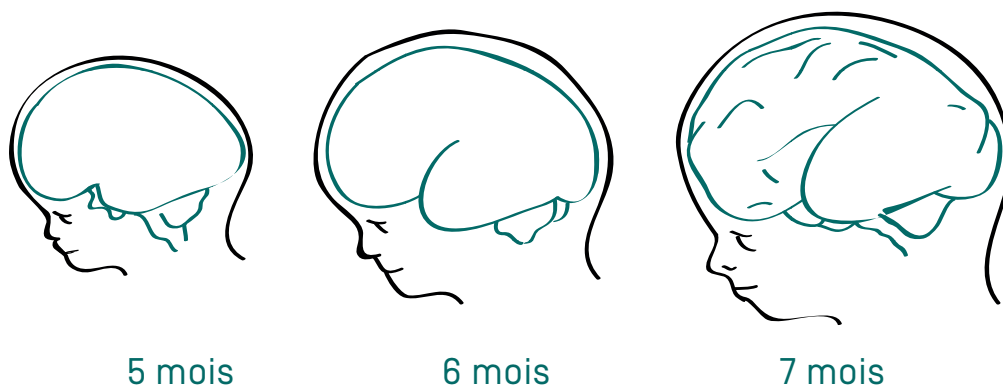
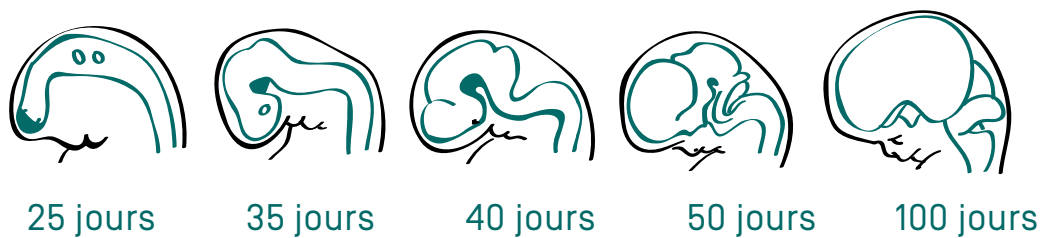


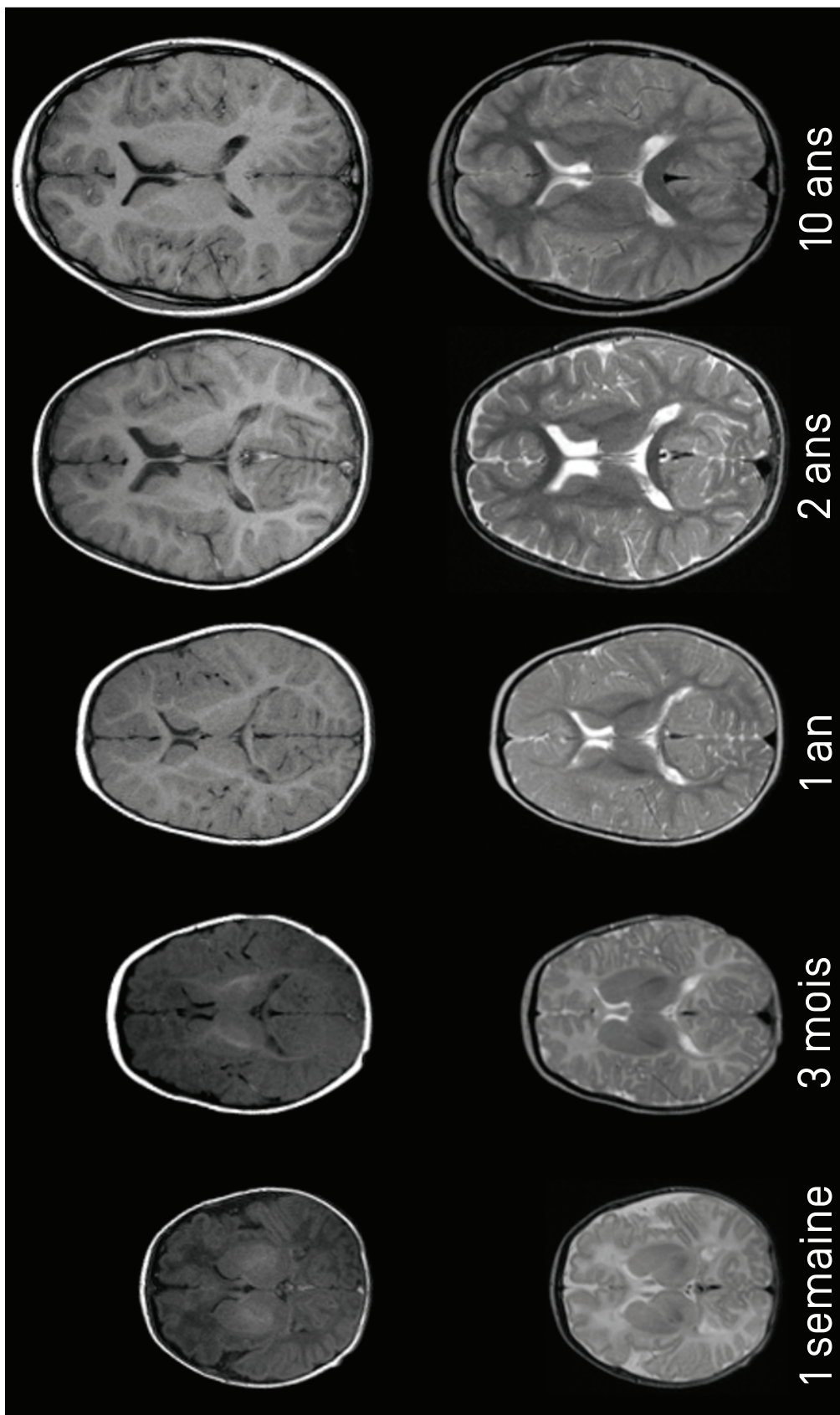
ANNEXE 7 : DÉVELOPPEMENT DE LA TAILLE DE L'ENFANT



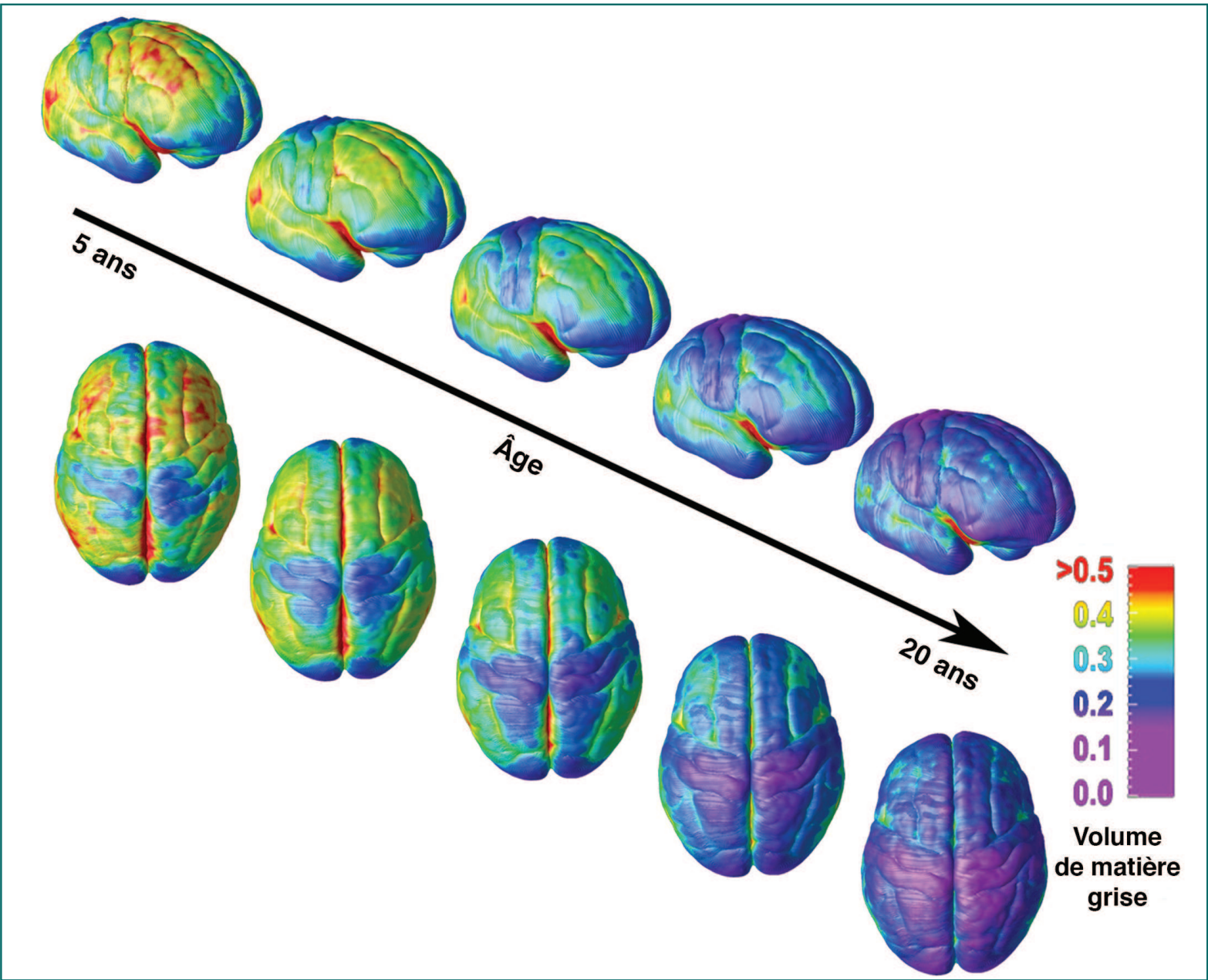
ANNEXE 8 : DÉVELOPPEMENT DU CERVEAU D'UN FŒTUS



ANNEXE 9 : DÉVELOPPEMENT DU CERVEAU D'UN ENFANT
[VUES DU DESSUS]



© NIH MRI Study of Normal Brain Development (Pediatric MRI Study)



Nitin Gogtay, Jay N. Giedd, Leslie Lusk, Kiralee M. Hayashi, Deanna Greenstein, A. Catherine Vaituzis, Tom F. Nugent III, David H. Herman, Liv S. Clasen, Arthur W. Toga, Judith L. Rapoport, and Paul M. Thompson, *Dynamic mapping of human cortical development during childhood through early adulthood*, PNAS 2004 101 [21] 8174-8179. © [2004] National Academy of Sciences, USA